

Dynamic Bulging of Intervertebral Discs in the Degenerative Lumbar Spine

Jun Zou, MD, MS,* Huilin Yang, MD, PhD,* Masashi Miyazaki, MD, PhD,†
Yuichiro Morishita, MD, PhD,† Feng Wei, MD, PhD,† Scott McGovern, MD,†
and Jeffrey C. Wang, MD,†

Study Design. The effect of postural change on degenerative lumbar discs was quantified using novel kinematic magnetic resonance imaging (kMRI).

Objective. The purpose is to describe the bulging of degenerative intervertebral lumbar discs *in vivo* subjected to different postural loads using a novel kMRI.

Summary of Background Data. Symptomatic lumbar disc degeneration is a leading cause of pain and disability throughout the world. Over 70% of US citizens will experience a debilitating episode of low back pain. Earlier reports of degenerative disc changes are cadaver studies or are performed with recumbent MRI that eliminates the functional effects of gravity and muscle power. Little data are available on the behavior of degenerative intervertebral discs *in vivo* under physiologic loads.

Methods. A total of 513 patients obtained kMRI. Disc bulging beyond the intervertebral space was quantified during upright neutral, flexion, and extension imaging. The degree of intervertebral disc degeneration was correlated using the Pfirrmann Classification.

Results. Moderately degenerated intervertebral discs (grade III and IV) demonstrated greater bulging than mildly degenerated discs (grade II). Severely degenerated discs (grade V) also showed a trend toward greater bulging, but this was not significant. Grade I discs at all levels moved posteriorly in flexion and anteriorly in extension when compared to neutral posture. However, mild to severe (grade II–V) degenerative discs behaved differently in response to postural loads. Extension resulted in significant posterior bulging, while flexion did not demonstrate obvious anterior derangement.

Conclusion. Disc bulging increases with the severity of disc degeneration. Grade I discs demonstrate the expected sagittal migration in response to postural load. However, more degenerative discs behave less predictably, and spine extension may result in significant posterior disc bulging. Degenerative changes in the intervertebral disc significantly affect the kinematic patterns under postural load *in vivo*. kMRI is a useful tool to quantify the kinematic behavior of degenerative intervertebral discs.

Key words: kMRI, disc degeneration, disc bulging, load-bearing, lumbar. **Spine 2009;34:2545–2550**

Symptomatic lumbar disc degeneration is a leading cause of pain and disability throughout the world. Chronic low back pain has been linked to the degenerative lumbar spine.¹ Spinal degeneration is a common problem that typically worsens with age and includes clinical conditions such as disc degeneration, facet joint osteoarthritis, vertebral body degeneration, and ligament degeneration.² Initial degenerative changes in the lumbar spine typically occur within the nucleus pulposus of the intervertebral disc.³ Normal discs function as shock absorbers. Injured and degenerative discs lose their function and the results in painful and unstable spines. The proteoglycan and water content in the nucleus pulposus decrease with disc degeneration.⁴ Nucleus pressure is therefore reduced and increased vertical loading of the anulus causes the disc to bulge outward radially.^{5–7} Few studies, most on cadaver specimens, have evaluated kinematic behaviors of intervertebral discs.^{8–10} These experiments suggested that the nucleus in healthy discs migrates in a posterior direction with flexion and in an anterior direction with extension. The motion pattern changes that occur *in vivo* are significantly more complex. The intervertebral discs exert internal swelling pressure, and this is an important disc-based response to axial compression.^{11,12} Magnetic resonance imaging (MRI) has been used in recent studies to examine disc morphology and displacement,^{13–15} and these studies consistently support the anterior migration of the nucleus pulposus when moving from flexion to extension. However, further studies are required to examine these effects concurrently since the correct bending geometry is difficult to reproduce. Muscle activity and pain responses complicate studies of *in vivo* motion, and the application of axial pressure to the disc is offset to induce flexion or extension. The segmental behavior of lumbar intervertebral discs, especially in degenerative disc disease, is not well understood.

Kinematic MRI (kMRI) allows imaging of patients in weight-bearing positions, in flexed positions, and in extended positions, and may allow a more thorough investigation of each patient and a better clarification of disease pathology. This study evaluated the use of the novel kMRI diagnostic modality in patients with chronic lower back pain. We investigated the effects of disc degenera-

From the *Department of Orthopaedic Surgery, The First Affiliated Hospital of Soochow University, Suzhou, Jiangsu, China; and †Department of Orthopaedic Surgery, University of California at Los Angeles, Los Angeles, CA.

Acknowledgment date: October 16, 2008. Revision date: April 6, 2009. Acceptance date: April 9, 2009.

The manuscript submitted does not contain information about medical device(s)/drug(s).

No funds were received in support of this work. No benefits in any form have been or will be received from a commercial party related directly or indirectly to the subject of this manuscript.

Address correspondence and reprint requests to Jeffrey C. Wang, MD, Department of Orthopaedics and Neurosurgery and Biomedical Engineering, UCLA Comprehensive Spine Center, 1250 16th St, Suite 745, Santa Monica, CA 90404; E-mail: jwang@mednet.ucla.edu

tion on the biomechanical and kinematic behaviors of the spine after disc degeneration.

Materials and Methods

Study Population

Patients with symptomatic back pain ($n = 513$) including those with radiculopathy or myelopathy were referred for kMRI imaging of the lumbar spine from February 2006 through February 2007. Detailed neurologic examinations and routine radiography were performed before MRIs in all patients. There were 215 males and 298 females enrolled in the study with a mean age of 42.6 years (range, 19–74 years). A total of 2565 lumbar discs were evaluated from all patients in this study.

Imaging Instrumentation

MRI of the lumbar spine was performed with a 0.6 Tesla MRI scanner (Fonar Corp. UPRIGHT, Multi-Position, New York, NY). The MRI unit used a vertical orientation of 2 opposing magnetic doughnuts spaced 18 inches apart and allowed scanning of the patient in an upright axially loaded position. Images were obtained with a quad channel planar coil. Images collected included T1-weighted sagittal spin echo images (repetition time, 671 milliseconds; echo time, 17 milliseconds; thickness, 4.0 mm; field of view, 30 cm; matrix, 256×224 ; NEX 2) and T2-weighted fast spin echo images (repetition time, 3000 milliseconds; echo time, 140 milliseconds; thickness, 4.0 mm; field of view, 30 cm; matrix, 256×224 ; NEX 2, flip angle).

Procedure

Patients were placed in an upright axially loaded neutral position (T1- and T2-weighted images) and in upright axially loaded flexion and extension positions (T2-weighted Fast Spin Echo images only). A total of 5 level units (L1–L2, L2–L3, L3–L4, L4–L5, and L5–S1) were chosen from these patients and assessed on the T2-weighted midsagittal images.

Points were marked for digitization by 3 spinal surgeons in each film. Vertebral bodies were marked at 4 points (anterior-inferior, anterior-superior, posterior-superior, and posterior-inferior) from L1 to S1. Disc migration on MRI images was recorded by computer-based measurements and all calculations were performed with the MRI Analyzer Version 3 (True-metric Corp, Bellflower, CA) anatomic software to for objective quantification. Disc bulging is measured as the extension of the disc beyond the intervertebral space; greater value represented greater posterior bulging. Our literature review yielded several factors important in the development of a comprehensive grading system to classify the degree of intervertebral disc degeneration in such cases (Table 1).^{16–20} T2-weighted sagittal

Table 1. Grading System for Lumbar Disc Degeneration

Grade	Nucleus Signal Intensity	Nucleus Structure	Distinction of Nucleus and Anulus	Disc Height
I	Hyperintense	Homogenous, white	Clear	Normal
II	Hyperintense	Inhomogenous with horizontal band, white	Clear	Normal
III	Intermediate	Inhomogenous, gray to black	Unclear	Normal to decreased
IV	Hypointense	Inhomogenous, gray to black	Lost	Normal to decreased
V	Hypointense	Inhomogenous, gray to black	Lost	Collapsed

Table 2. The Analysis of Intra- and Interobserver Reliability

Intraobserver	Kappa Coefficient	Interobserver	Kappa Coefficient
No.1	0.907	No.1–No.2	0.779
No.2	0.950	No.1–No.3	0.752
No.3	0.933	No.2–No.3	0.730

images were used by 3 spine surgeon observers to grade all cases of lumbar intervertebral disc degeneration in a blinded fashion. All the MRIs were separately analyzed with a minimum interval of 1 week.

Statistical Analysis

Statistical analysis was performed using the computer program SPSS (version 13, SPSS Inc, Chicago, IL), and values were expressed as mean \pm standard deviation. Student *t* test was performed with a significance level of 0.05. The analysis of intra- and interobserver reliability was estimated using kappa statistics²¹ and interpreted according to the guidelines suggested by Landis and Koch.²² The levels of agreement were rated as follows: kappa value of 0 to 0.2 indicated poor agreement; 0.21 to 0.4, fair agreement; 0.41 to 0.60, moderate agreement; 0.61 to 0.8, substantial agreement; and 0.81, upward excellent agreement. Value 1 indicated absolute agreement, whereas 0, agreement no better than chance.

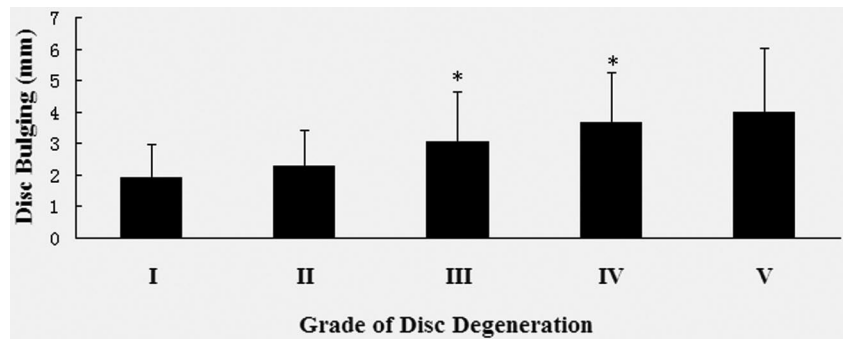
Results

Grading of disc degeneration (Table 1) showed excellent intraobserver agreement among 3 spinal surgeons ($\kappa = 0.924–0.957$). As expected, interobserver agreement was relatively lower than intraobserver agreement. Interobserver agreement ranged from 0.771 to 0.807. Estimated kappa values for intra- and interobserver analysis are summarized in Table 2.

The magnitude of disc bulging at each level was correlated with disc degeneration and dynamic postural loading. Disc bulging increased in magnitude with increasing degeneration at each lumbar level. Mildly degenerated (grade II) discs bulged less ($P < 0.05$) than more degenerated discs (both grade III and IV) (Figure 1). Grade III discs bulged greater distances than grade II discs ($P < 0.05$). Likewise, grade IV discs bulged greater than grade III discs ($P < 0.05$) at all levels (Table 3). This trend was also noted in grade V discs (severe degeneration) although statistically significant differences were not observed. Mildly (grade II) degenerative discs also demonstrated greater disc bulging ($P < 0.05$) than minimally (grade I) degenerated discs at the L4–L5 and L5–S1 levels.

The direction of disc movement at each level was assessed in upright flexion and extension positions relative to neutral posture. Grade I discs at all levels moved in a posterior direction in flexion and in an anterior direction in extension when compared to neutral posture. Grade II discs moved in a posterior direction during flexion at L1–L2, L2–L3, L3–L4, and L4–L5, and during extension at L5–S1. Grade III discs moved in a posterior direction during flexion at L1–L2 and L3–L4, and during

Figure 1. Total disc bulging with different disc degeneration. Compared to previous grade, there were significant differences between grade II and III and between grade IV and V at total disc bulging. * $P < 0.05$ compared to previous grade.



extension at L2–L3. Grade IV discs moved in a posterior direction during flexion at L4–L5, and moved in an anterior direction during extension at L3–L4 and L-4 and in a posterior direction at L5–S1. All grade V discs moved in a posterior direction during flexion at L2–L3 (Figures 2–6).

Discussion

Degenerative disc disease is a prevalent problem that generally increases with age. Disc degeneration commences as early as the second decade of life.²³ Approximately 40% of individuals with lower back pain may experience discogenic pain.^{24,25} The well functioning spine must perform load-bearing activities, provide movement, and protect the neural elements.²⁶ The first 2 roles include supporting the bending moments of the head and upper torso, and allowing motion at the interval between the torso and the pelvis. Intervertebral discs provide flexibility to the spine during bending and rotation, and transmit loads received from body weight and muscle activity. Therefore, disc degeneration directly affects the load bearing and motion of the spine, and indirectly affects the capability of the spine to protect the neural elements.

Initial degenerative processes most commonly occur with the intervertebral disc. Disc space narrowing may be the initial structural difference noted in the degenerative lumbar spine. However, after remodeling of disc-vertebra interfaces, both vertebral rim osteophytes and disc herniation will form as a result of degenerative processes.²⁷ We demonstrated in this study that disc bulging increased with the severity of disc degeneration. The layers of the annulus can separate in areas and form circum-

ferential tears during disc degeneration, and several of these circumferential tears may unite and result in a radial tear where material may herniate and produce disc herniation and prolapse. Greater changes were noted at lower spinal levels (L4–L5 and L5–S1) in our study. These results are in accordance with general theories of disc herniation pathology. Previous studies have shown that most disc derangements are seen in the spinal segments with greatest mobility.^{28,29} The intervertebral disc modifies its shape in response to motion and recoils back to its original shape after the motion is completed. As a result, excessive motion can result in the herniation of both previously compromised and healthy discs. Knop-Jergas *et al*²⁸ have reported that 58.7% of herniations occur at the L4–L5 level.

Displacement of the nucleus in response to spinal position may be important in the treatment of spinal pain. Prone extension is a posture commonly used as a therapeutic technique in physical therapy. McKenzie recommends extension exercises in the treatment of posterior disc derangement because of stress reduction on the pain-sensitive posterior annulus due to anterior displacement of the nucleus.³⁰ Clinical studies, clinical models, and cadaver studies consistently support the clinical concept of anterior migration of the nucleus pulposus during movements from flexion to extension. Internal pressure is maintained by a well-hydrated and proteoglycan-rich nucleus pulposus in the healthy adult disc.³¹ All grade I discs in our study moved in a posterior direction during flexion and in an anterior direction during extension, although these trends were not statistically significant. However, we noted a paradoxical response in grade II to V disc disease, which has not been reported in previous studies. Abnormal discs behave less predictably than normal discs, and extension may result in significant posterior disc bulging. Moreover, flexion did not show obvious anterior derangement.

Changes in motion patterns that occur with disc degeneration are complex. Structural and biochemical degenerative changes within discs are likely to affect disc responses to positional changes. *In vivo* motion is complicated by muscle activity and pain. Therefore, it is difficult to anticipate stereotypical responses within degenerative discs to positional change. These results question popular therapeutic techniques. Certain passive move-

Table 3. Disc Bulging at Each Level With Differential Degeneration (mm)

Level/ Grade	I	II	III	IV	V
L1–L2	2.05 ± 1.15	1.95 ± 0.96	2.19 ± 1.01*	2.75 ± 1.25*	3.83 ± 1.33
L2–L3	1.63 ± 0.48	2.16 ± 1.05	2.63 ± 1.26*	3.19 ± 1.47*	3.45 ± 1.74
L3–L4	1.89 ± 1.89	2.41 ± 1.11	2.77 ± 1.21*	3.59 ± 1.29*	3.95 ± 1.20
L4–L5	1.90 ± 1.04	2.75 ± 1.17*	3.58 ± 1.57*	4.00 ± 1.56*	4.68 ± 2.17
L5–S1	2.13 ± 1.16	2.61 ± 1.35	3.61 ± 1.92*	3.90 ± 1.72	3.78 ± 2.15

Values are expressed as mean ± SD.

* $P < 0.05$ compared to previous grade at same level.

Figure 2. Dynamic change of L1/2 disc bulging with degeneration. Compared to neutral view, there were significant differences in the extension view of grade II and grade III. * $P < 0.05$ compared to neutral view.

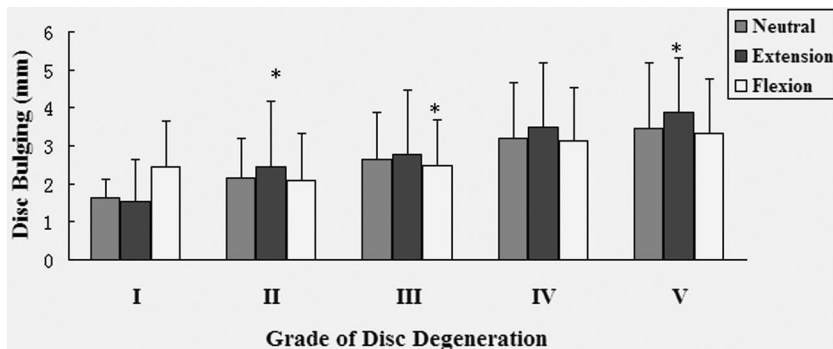
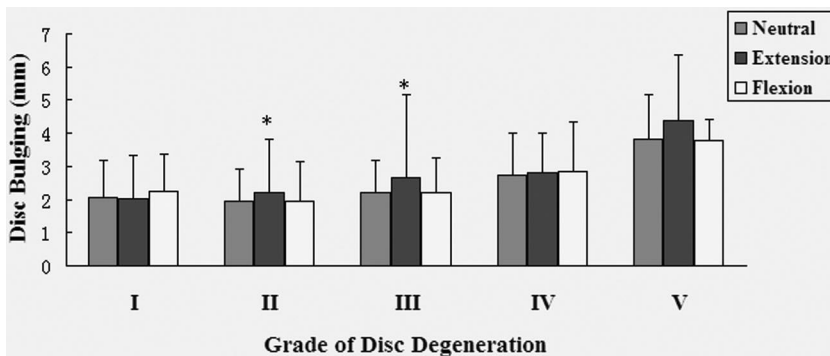


Figure 3. Dynamic change of L2/3 disc bulging with degeneration. Compared to neutral view, there were significant differences in the extension view of grade II and grade IV, and in the flexion view of grade III. * $P < 0.05$ compared to neutral view.

Figure 4. Dynamic change of L3/4 disc bulging with degeneration. Compared to neutral view, there were significant differences in the extension view of grade II and grade III, and in the flexion view of grade IV. * $P < 0.05$ compared to neutral view.

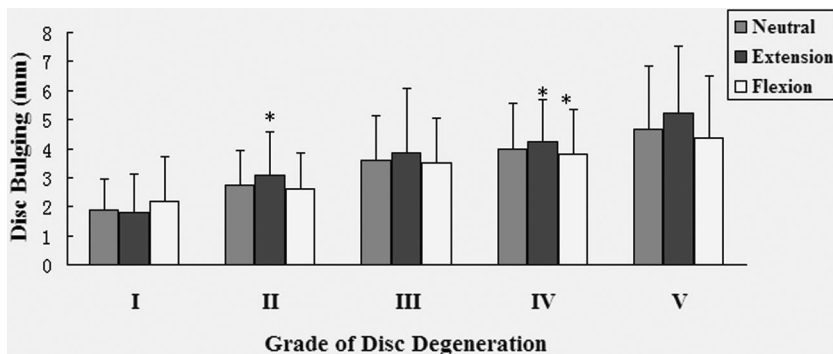
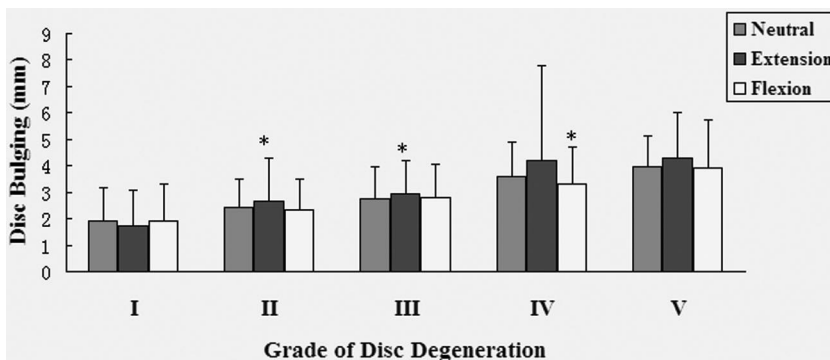
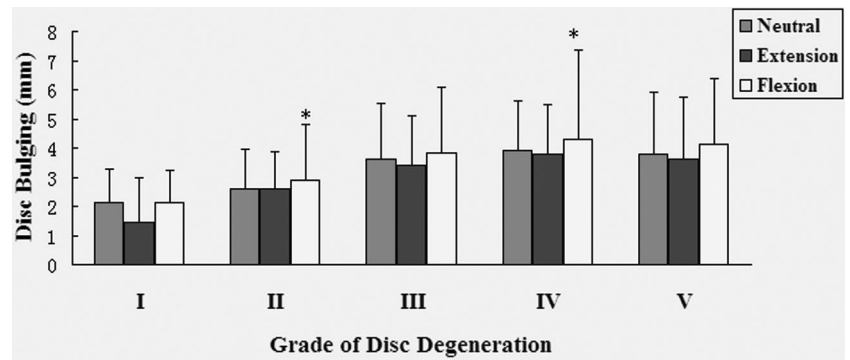


Figure 5. Dynamic change of L4/5 disc bulging with degeneration. Compared to neutral view, there were significant differences in the extension view of grade II and grade IV, and in the flexion view of grade IV. * $P < 0.05$ compared to neutral view.

ment techniques and exercises are not beneficial in the management of lower back pain in advanced degenerative disc disease, and this reinforces the thought that decisions related to movement direction or spinal position should be based on clinical symptoms rather than on biomechanical theory. Further study is required to correlate our results with the complex motions of the degenerative spine *in vivo*.

The use of quantitative MRI to investigate lumbar disc disease is a relatively recent development and study results should be cautiously interpreted with regard to measurement issues.³² MRI is a valuable method in the detection of lumbar spinal pathology, and correlation of abnormal MRI findings with clinical features in the patient is important in the corroboration of the clinical diagnosis and the construction

Figure 6. Dynamic change of L5/S1 disc bulging with degeneration. Compared to neutral view, there were significant differences in the flexion view of grade II and grade IV. * $P < 0.05$ compared to neutral view.



of an appropriate management plan. The determination of disc margins is difficult using MRI, particularly in discs that demonstrate any degree of degenerative change,³³ and the results in poor measurement repeatability especially when positional changes are small. The novel kMRI provides strong objective data, and analyzes images with proprietary software that both assists in the identification and quantification of anatomic abnormalities. The measurement reliability of kMRI precisely quantified anatomic data, and proved a valuable tool with potential to further investigate lumbar disc morphology and spinal mechanics.

Key Points

- A novel kinematic MRI enables analysis of the dynamic postural and functional changes of degenerative lumbar discs.
- Greater disc bulging under postural loading occurs with advancing degenerative disc disease. Increasing bulging was noted at lower spinal levels (L4–L5 and L5–S1).
- Prone extension is a posture commonly used in physical therapy. Based on our study, grade I discs displayed the expected response to dynamic positions. However, more degenerative discs behave less predictably, and extension may result in significant posterior disc bulging. These results question the popular therapeutic techniques.

References

1. Vanharanta H, Sachs BL, Spivey MA, et al. The relationship of pain provocation to lumbar disc deterioration as seen by CT/discography. *Spine* 1987;12:295–8.
2. Fujiwara A, Lim TH, An HS, et al. The effect of disc degeneration and facet joint osteoarthritis on the segmental flexibility of the lumbar spine. *Spine* 2000;25:3036–44.
3. Buckwalter JA. Aging and degeneration of the human intervertebral disc. *Spine* 1995;20:1307–14.
4. Urban JP, McMullin JF. Swelling pressure of the intervertebral discs: influence of age, spinal level, composition, and degeneration. *Spine* 1988;13:179–87.
5. Adams MA, McNally DS, Dolan P. “Stress” distributions inside intervertebral discs: the effects of age and degeneration. *J Bone Joint Surg Br* 1996;78:965–72.
6. Sato K, Kikuchi S, Yonezawa T. In vivo intradiscal pressure measurement in healthy individuals and in patients with ongoing back problems. *Spine* 1999;24:2468–74.
7. Brinckmann P, Grootenboer H. Change of disc height, radial disc bulge, and intradiscal pressure from discectomy: an in vitro investigation on human lumbar discs. *Spine* 1991;16:641–6.
8. Shah JS. *The Lumbar Spine and Back Pain*. Jayson MI, ed. 2nd ed. London: Pitman; 1980:359–405.
9. Shepperd JA. The inside world of the disc. In: Shepperd JA, ed. *Proceedings of the Society for Back Pain Research*. St Leonards-on-Sea, Australia: Conquest Hospital; 1991:37–8.
10. Shepperd JA, Rand C. *Internal Disc Dynamics*. St Leonards-on-Sea, Australia: Conquest Hospital; 1992. Privately circulated video recording.
11. Hukins DW. A simple model for the function of proteoglycans and collagen in the response to compression of the intervertebral disc. *Proc R Soc Lond B Biol Sci* 1992;249:281–5.
12. Urban JP, Maroudas A. The measurement of fixed charge in the intervertebral disc. *Biochim Biophys Acta* 1979;586:166–78.
13. Beattie P, Brooks W, Rothstein J, et al. Effect of lordosis on the position of the nucleus pulposus in supine subjects. *Spine* 1994;19:2096–102.
14. Botsford DJ, Esses SI, Ogilvie-Harris DJ. In vivo diurnal variation in intervertebral disc volume and morphology. *Spine* 1994;19:935–40.
15. Brault JS, Driscoll DM, Laakso LL, et al. Quantification of the lumbar intradiscal deformation during flexion and extension, by mathematical analysis of the magnetic resonance imaging pixel intensity profiles. *Spine* 1997;22:2066–72.
16. Kolstad F, Myhr G, Kvistad KA, et al. Degeneration and height of cervical discs classified from MRI compared with precise height measurements from radiographs. *Eur J Radiol* 2005;55:415–20.
17. Kettler A, Rohlmann F, Neidlinger-Wilke C, et al. Validity and interobserver agreement of a new radiographic grading system for intervertebral for intervertebral disc degeneration, part II: cervical spine. *Eur Spine J* 2006;15:732–41.
18. Benneker LM, Heini PF, Anderson SE, et al. Correlation of radiographic and MRI parameters to morphological and biochemical assessment of intervertebral disc degeneration. *Eur Spine J* 2005;14:27–35.
19. Luoma K, Vehmas T, Riihimäki H, et al. Disc height and signal intensity of the nucleus pulposus on magnetic resonance imaging as indicators of lumbar disc degeneration. *Spine* 2001;26:680–6.
20. Pfirrmann CW, Metzendorf A, Zanetti M, et al. Magnetic resonance classification of lumbar intervertebral disc degeneration. *Spine* 2001;26:1873–8.
21. Cohen JA. A coefficient of agreement for nominal scales. *Educ Psychol Meas* 1960;20:37–46.
22. Landis JR, Koch GG. The measurement of observer agreement for categorical data. *Biometrics* 1977;33:159–74.
23. Nerlich AG, Schleicher ED, Boos N. 1997 Volvo award winner in basic science studies: immunohistologic markers for age-related changes of human lumbar intervertebral discs. *Spine* 1997;22:2781.
24. Schwarzer AC, Aprill CN, Derby R, et al. The prevalence and clinical features of internal disc disruption in patients with chronic low back pain. *Spine* 1995;20:1878–83.
25. Hammer M. Discogenic pain. *J Turkish Soc Algol*. 2002;14:7–16.
26. White AA, Panjabi MM. *Clinical Biomechanics of the Spine*. 2nd ed. Philadelphia, PA: Lippincott; 1990.
27. Battié MC, Videman T, Parent E. Lumbar disc degeneration: epidemiology and genetic influences. *Spine* 2004;29:2679–90.
28. Knop-Jergas BM, Zucherman JE, Hsu KY, et al. Anatomic position of a herniated nucleus pulposus predicts the outcome of lumbar discectomy. *J Spinal Disord* 1996;9:246–50.
29. Kanayama M, Abumi K, Kaneda K, et al. Phase lag of the intersegmental motion in flexion-extension of the lumbar spine: an in vivo study. *Spine* 1996;21:1416–22.

30. McKenzie RZ. *The Lumbar Spine: Mechanical Diagnosis and Therapy*. Waikanae, New Zealand: Spinal Publications; 1989.
31. Taylor JR, Giles LG. Lumbar intervertebral discs. In: Giles LG, Singer KP, eds. *Clinical Anatomy and Management of Low Back Pain*. Oxford: Butterworth-Heinemann; 1997:49–71.
32. Boos N, Wallin A, Schmucker T, et al. Quantitative MR imaging of lumbar intervertebral disc and vertebral bodies: methodology, reproducibility, and preliminary results. *Magn Reson Imaging* 1994;12:577–87.
33. Urban JP, Roberts S. Chemistry of the intervertebral disc in relation to functional requirements. In: Boyling J, Palastanga N, eds. *Grieve's Modern Manual Therapy*. 2nd ed. Edinburgh, United Kingdom: Churchill Livingstone; 1994:163–75.